



polydentia
swiss manufacture 

CLINICAL CASE

class IV restoration on a lateral incisor using Unica Proximal

courtesy of Dr. Mohammed Al Hasani
Iraq



Dr. Mohammed Al Hasani, Iraq



Dr Al Hasani graduated in Dentistry from Babylon University in 2017. He has attended many national and international restorative dentistry courses, focusing mainly in direct composite restorations. In 2020, he completed a StyleItaliano professional diploma course in Iraq. Dr Al Hasani currently teaches courses in direct composite restorations, focusing on posterior composite restorations, sharing his professional passion both inside and outside of Iraq.

product used

The Polydentia products used in this clinical case are:



**Unica
proximal**
anterior matrices

class IV restoration on a lateral incisor using Unica Proximal

Case report

The patient came to our practice for a routine check-up. An initial analysis revealed a class IV carious lesion on lateral incisor 12. We decided to eliminate the carious lesion and proceed with a direct composite restoration of the cavity.

The following case study shows the step-by-step restoration procedure using the Polydentia Unica Proximal anterior matrix.

preoperative

cavity
preparation

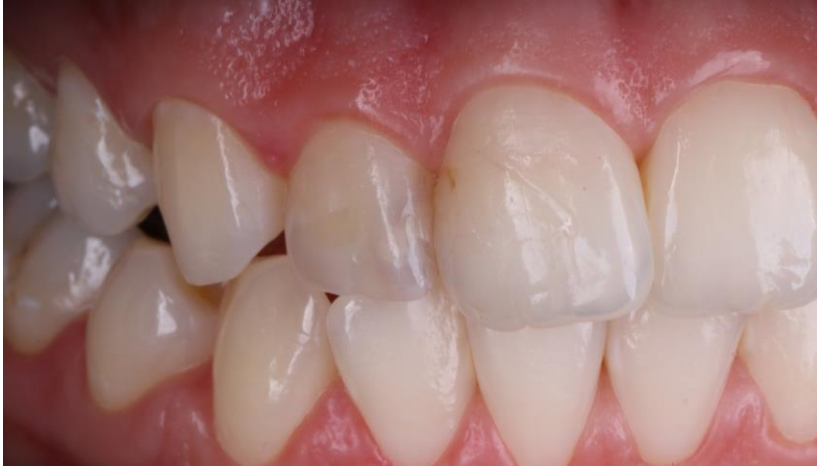matrixing

restoration

outcome

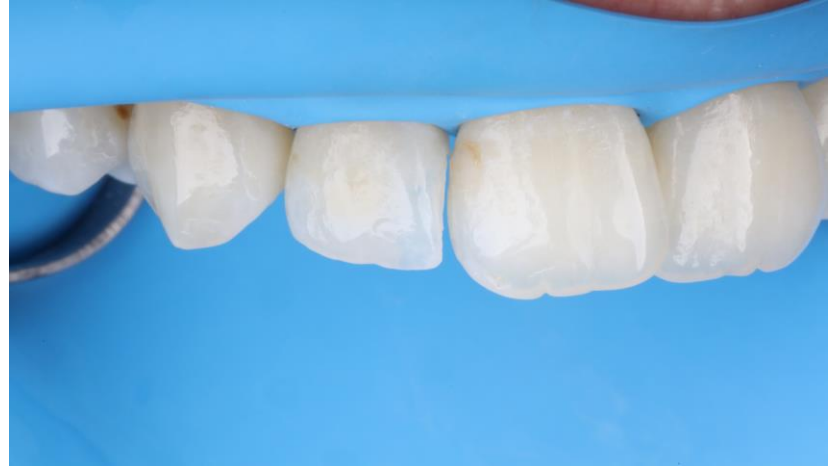

01



Preoperative view of the carious lesion on lateral incisor 12.

02



The quadrant under isolation with a rubber dam.

preoperative

cavity
preparation

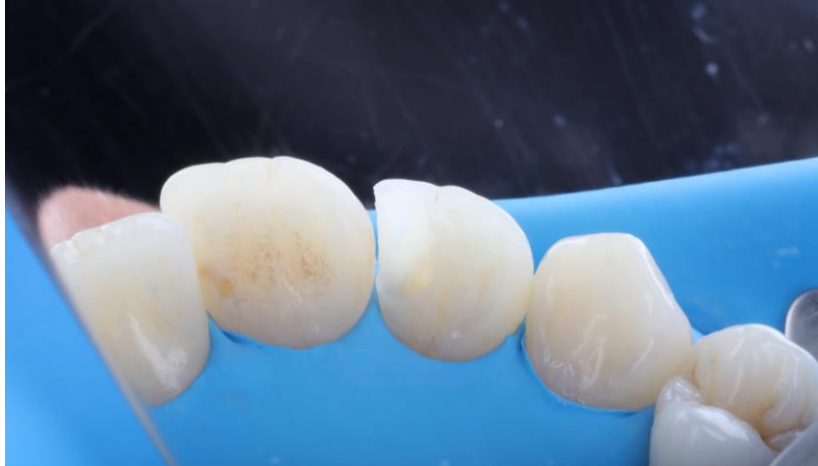matrixing

restoration

outcome



03



Clinical situation after removal of the carious lesion, cleaning of the proximal area and disinfection.

preoperative

cavity
preparation

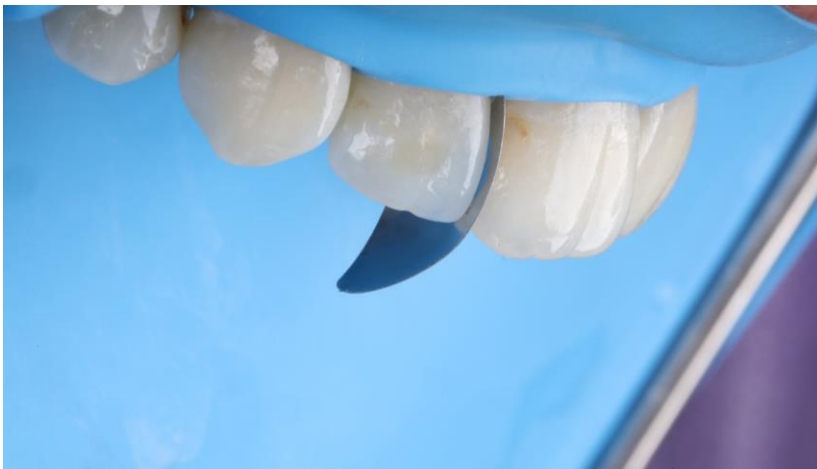matrixing

restoration

outcome

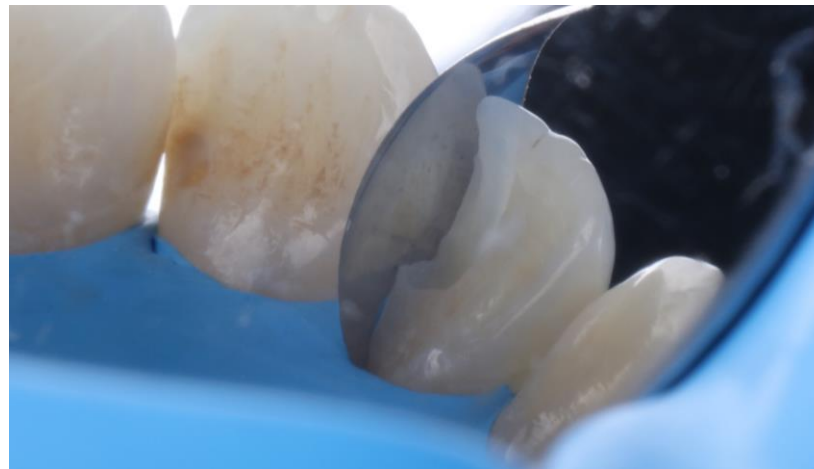

04



Unica Proximal placed mesially on tooth 12.

05



The cervical labiopalatal arch of the matrix allows it to slide subgingivally easily and increases the stability of the matrix (even without a wedge).

preoperative

cavity
preparation

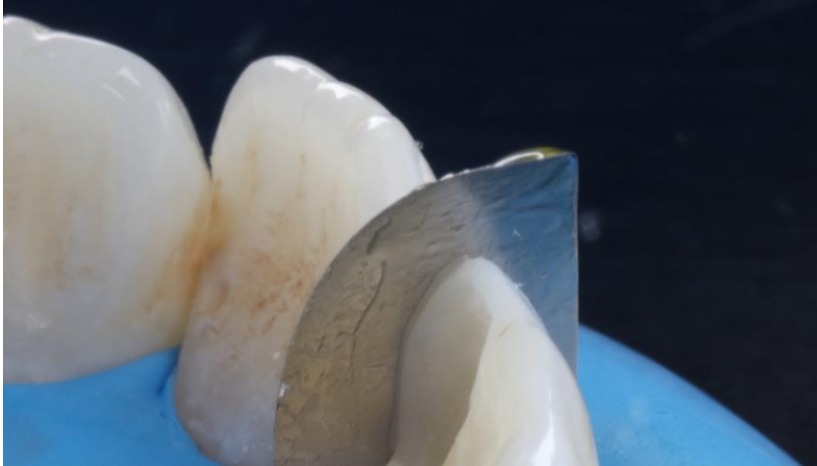
matrixing

restoration

outcome



06



Reconstruction of the proximal wall on incisor 12. The contouring of the matrix reproduces the natural proximal morphology of the tooth.

preoperative

cavity
preparation

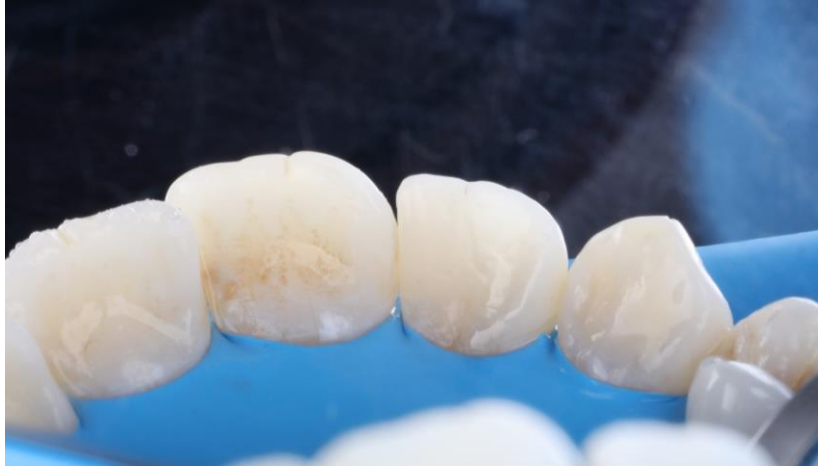matrixing

restoration

outcome

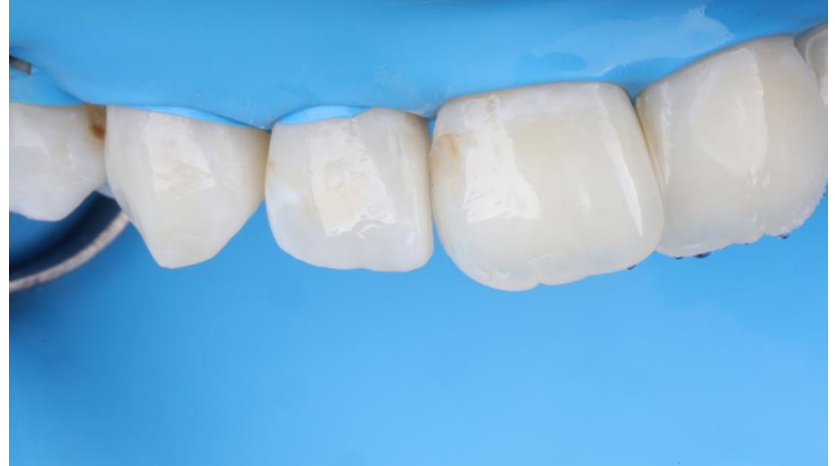

07



Reconstruction of the palatal wall.

08



Clinical situation after the reconstruction of the incisor surfaces, finishing and polishing.

preoperative

cavity
preparation

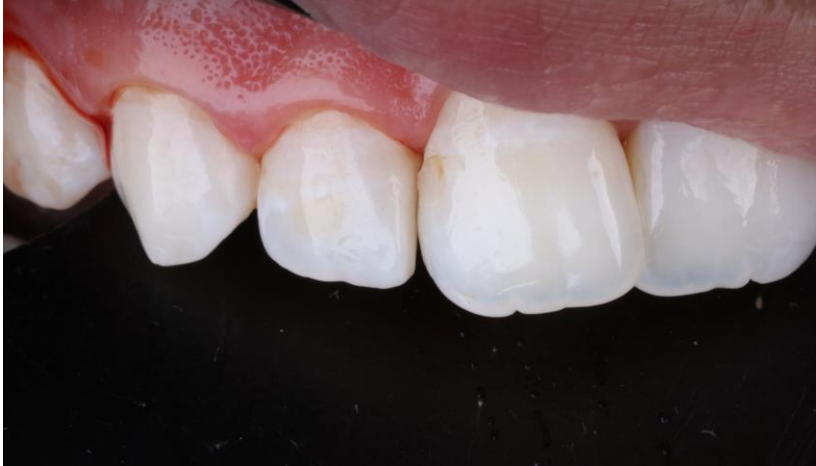matrixing

restoration

outcome

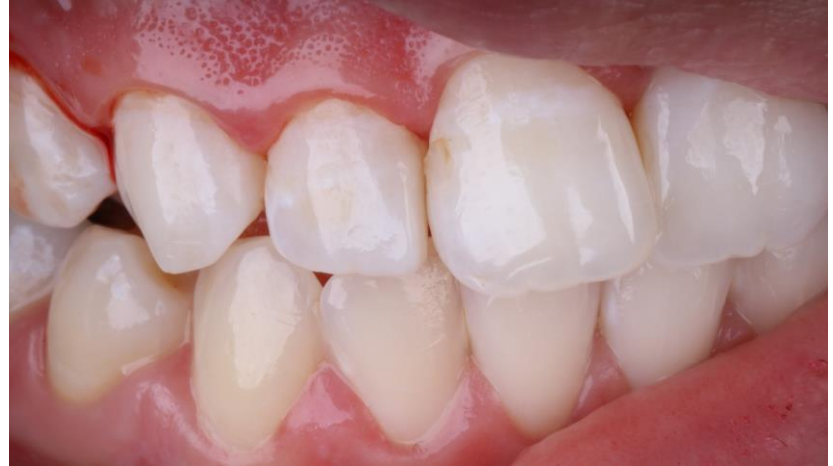

09



Immediate postoperative images after rubber dam removal.

10



Final result.

class IV restoration on a lateral incisor using Unica Proximal

Conclusion

Stabilising the matrix in order to rebuild the inter proximal wall is usually one of the most challenging aspects of class IV situations. Using Unica Proximal, conceived in partnership with StyleItaliano, overcomes this issue. The cervical labiopalatal arch of the matrix allows it to slide subgingivally easily and increases the stability of the matrix (even without a wedge). Ultimately, the restoration is straight-forward and rapid and results in a natural anatomical tooth morphology.

clinical case courtesy of Dr. Mohammed Al Hasani, Iraq



MKTG-0093-CC-EN REV 00 04.2024 © Polydentia SA, 2024. All rights reserved. Polydentia, the Polydentia logotype and all other trademarks are trademarks of Polydentia, unless stated otherwise or made obvious by the context in a certain case. Product images are not necessarily to scale. Disclaimer: Some products may not be available for sale in all countries. Please contact your local Polydentia distributor (www.polydentia.ch/en/distributors/) for information on the current product assortment and availability. The Polydentia products mentioned are for professional use only. Not all medical devices used during the case were Polydentia devices. The full procedure is not shown. Certain sequences have been omitted. Please refer to the relevant IFUs, where available, for full instructions. Polydentia is a medical device manufacturer and does not dispense medical advice. Polydentia does not accept any liability for injuries or damage to individuals or property resulting from the application of this clinical case. The purpose of this clinical case is not to recommend measures, techniques, procedures or products, or give advice, and it is not a substitute for medical training or your own clinical judgement as a healthcare professional. Viewers should never disregard professional medical advice or delay seeking medical treatment as a result of something they have seen in this clinical case. The opinions expressed are those of the individual doctor. Clinicians should use their own professional judgment when treating their patients. Individual patient outcomes may vary.

thanks for your attention!

Contact us

 Via Cantonale 47, 6805 Mezzovico-Vira, Switzerland

 info@polydentia.ch

 www.polydentia.ch

Follow us

 facebook.com/polydentia

 [@polydentia](https://www.instagram.com/polydentia)

 www.youtube.com/user/POLYDENTIASA

